Intimate Partner Homicide by Rifle Gunshot Injury to Head: A Case Report

Chepyala Laxman Rao [1], Chaitanya Mittal [2], Sundaragiri Suraj [3]

[1] Department of Forensic Medicine Kakatiya medical College, Warangal, Telangana,India.
[2] Department of Forensic Medicine & Toxicology, AIIMS Patna,India.
[3] Department of Forensic Medicine and Toxicology, Gandhi Medical College, Secunderabad, Telangana, India.

Corresponding Author
Dr. Chaitanya Mittal | Email: dr.chaitanya13957@aiimspatna.org
Received:Novemeber 08,2025; Accepted: february 23,2026 DOI: https://doi.org/10.66644/AJFM/20250203

Abstract

Firearm injuries to the head are associated with a high fatality rate due to severe damage to vital craniocerebral structures. Intimate partner homicide of women victims is about 4-5 times higher than that of men. Although femicide–suicide cases are documented in literature, homicidal firearm injuries inflicted by intimate partners remain uncommon in the Indian setting. We report a rare case of intimate partner homicide involving a service rifle, emphasizing the forensic findings, medico-legal interpretation, and preventive implications.

Keywords : Gunshot injury; Head injury; Perforating craniocerebral injury; Intimate partner homicide; Homicide

Introduction

Gunshot injuries to the head are among the most common lethal firearm injuries encountered in forensic practice [1]. The manner of death due to firearm injuries—suicide, accident, or homicide—varies with geographical, socio-cultural, and legal factors. Intimate partner homicide of women victims is higher than that of men. The World Health Organization defines homicide as the killing of a person by another with intent to cause death or serious injury [2]. In 2019, an estimated 475,000 people worldwide were victims of homicide with a global rate of 6.2 per one lakh population. In females with age of 15-29 years, accounting for nearly 20% of cases about a global rate of 2.4 per one lakh population [2]. According to the National Crime Records Bureau of India, 29,272 homicides were reported in 2021, with interpersonal disputes being the most common motive, followed by personal vendetta or enmity, gain, and love affairs [3]. Intimate partner homicide predominantly affects women and is often perpetrated by a known individual [4]. The present report describes a rare case of homicidal firearm injury to the head committed by an intimate partner using a service weapon.

Case Description

A 22-year-old unmarried female police constable belonging to a low socio-economic background sustained a firearm injury when she was shot by her male colleague using his .303 service rifle in the early hours of the morning. The incident occurred inside the police station while the victim was asleep in the rest room. Preliminary investigation revealed that the motive was her refusal to marry the accused. After shooting the victim, the accused attempted suicide by firing at his chest. Both were rushed to a corporate hospital, where the victim succumbed to her injuries during treatment. A suicide note recovered from the accused revealed his intent to kill the victim and subsequently commit suicide.

On external examination, blood-stained clothes were present. Four crescentic abrasions each measuring approximately 0.25 cm in diameter were

© Author(s) 2026. Published by the Academy Journal of Forensic Medicine (ISSN: 3107-7633). This is an open-access article distributed under the terms of the Creative Commons Attribution–Non Commercial 4.0 International License (CC BY-NC 4.0), which permits non-commercial use, distribution, and reproduction in any medium, provided the original work is properly cited.

noted over the upper part of the right lateral chest on autopsy. A through-and-through firearm injury was present over the head, with the entry wound located over the right temporal region of the scalp, (Fig.1), 7 cm above the mastoid prominence, measuring about 0.5 cm in diameter, showing inverted margins with surrounding tattooing and singeing of scalp hair. On reflection of the scalp, a perforating fracture of the temporal bone (Fig.2 & Fig.3), with radiating fractures involving the temporal, parietal, and occipital bones was observed. The projectile traversed the brain and exited through the left parietal bone, producing an exit wound over the left parietal region of the scalp measuring 2 × 1 cm with everted margins, located 9 cm above and lateral of left eye brow (Fig.4 & Fig.5), and an associated comminuted fracture and sagittal sutural fracture measuring over an area of 15 x 10 cm (Fig.6). Multiple cotton swabs samples taken from entry and exit wound and room dried clothes of deceased send for GSR analysis by maintaining chain of custody. The cause of death was opined as bullet injury to the head.

Discussion

Homicidal head injuries in India are most commonly caused by blunt force trauma, with firearm-related head injuries being relatively uncommon. Sundaragiri et al. reported that blunt weapons accounted for the majority of homicidal head injuries with skull fractures, while firearm injuries were rarely encountered with majority of male victims of age between 21 and 30 years [5]. In contrast, the present case involved a high-velocity rifled firearm case of young female, resulting in extensive craniocerebral destruction and immediate fatality.

Studies by Kumari et al. and Sachan et al. have demonstrated that firearm homicides pre dominantly affect young male adults, with homicide being the most common manner of death and rifled firearms frequently used with most common site of firearm injury was the abdomen & the head while our case has injury only over the head[6,7]. Similar observations regarding demographic trends and weapon type have been reported by DiMaio and DiMaio, who emphasized the lethality of close-range rifled firearm injuries to the head [8].

Patowary observed that chest injuries were more common than head injuries in homicidal firearm deaths[9]. However, head injuries are associated with higher fatality rates, especially when vital brain structures are involved. Knight and Saukko highlighted that deliberate targeting of the head is indicative of clear homicidal intent and is frequently associated with instant incapacitation [10].

The present case occurred within a police station, underscoring the medico-legal implications of institutional firearm access. Studies have shown that occupational access to firearms significantly increases the risk of firearm-related homicide and suicide. A systematic review by Anglemyer et al. demonstrated a strong association between firearm access and increased risk of violent death [11].

The sequence of homicide followed by attempted suicide aligns with the intimate partner homicide–suicide phenomenon described in previous literature. Dawson reviewed such cases and noted that firearms are commonly used where access is readily available, often resulting in fatal outcomes [12].

Conclusion

Gunshot injuries to the head are almost invariably fatal due to extensive damage to vital brain structures. This case underscores the medico-legal importance of strict firearm regulation, controlled access to service weapons, and periodic psychological evaluation of police personnel. Preventive strategies such as counseling services, early identification of interpersonal conflicts, and institutional intervention may help reduce the risk of such tragic incidents. From a forensic perspective, meticulous documentation, scene of incident visit, proper postmortem examination with shaving of scalp hairs, sample preservation in case of firearm injuries is essential in establishing the manner of death in complex homicide–suicide scenarios.

Source of Funding

None.

Conflict of Interest

None.

References

1. Rosenfeld JV. Gunshot injury to the head and spine. Journal of Clinical Neuroscience. 2002;9(1):9–16.
2. World Health Organization. Violence Info: Homicide. WHO Global Health Estimates (2019 update). Geneva: WHO; 2020.
3. National Crime Records Bureau. Crime in India 2021. Ministry of Home Affairs, Government of India, New Delhi.
4. Campbell JC, Glass N, Sharps PW, Laughon K, Bloom T. Intimate partner homicide: Review and implications of research and policy. Trauma, Violence & Abuse. 2007;8(3):246–269.
5. Sundaragiri S, Koppada V, Tandur S. The epidemiology and patterns of head injuries with skull fractures in homicidal deaths. Journal of Indian Academy of Forensic Medicine. 2017;39(3):248–254.
6. Kumari S, Rajput AS, Agarwal A, Arif A, Chaturvedi RK. Medico-legal aspects of firearm injury cases in Agra region. Journal of Indian Academy of Forensic Medicine. 2014;36(4):387–390.
7. Sachan R, Kumar A, Verma A. Frequency of firearm injuries, deaths and related factors in Kanpur, India. International Journal of Medical Toxicology and Forensic Medicine. 2013;3(3):88–95.
8. DiMaio VJ, DiMaio D. Forensic Pathology. 2nd ed. Boca Raton: CRC Press; 2001.
9. Patowary AJ. Study of pattern of injuries in homicidal firearm injury cases. Journal of Indian Academy of Forensic Medicine. 2005;27(2):92–95.
10. Saukko P, Knight B. Knight's Forensic Pathology. 4th ed. Boca Raton: CRC Press; 2016.
11. Anglemyer A, Horvath T, Rutherford G. The accessibility of firearms and risk for suicide and homicide victimization among household members: A systematic review. Annals of Internal Medicine. 2014;160(2):101–110.
12. Dawson M. Examining the decline in intimate partner homicide: A comparative study of Canada and the United States. Homicide Studies. 2005;9(4):280–296.

Figures with legends

Figure 1 Bullet Entry Injury

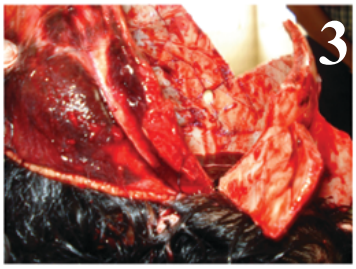

Figure 2. Bullet Entry Injury of Inner Scalp
Figure 3. Bullet Entry Injury of Skull

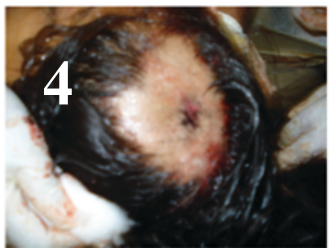

Figure 4. Bullet Exit Injury
Figure 5. Exit Injury over Skull
Figure 6. Comminuted fracture and sagittal sutural fracture